



# PRACTICAL OBSTETRICS 5<sup>TH</sup> STAGE

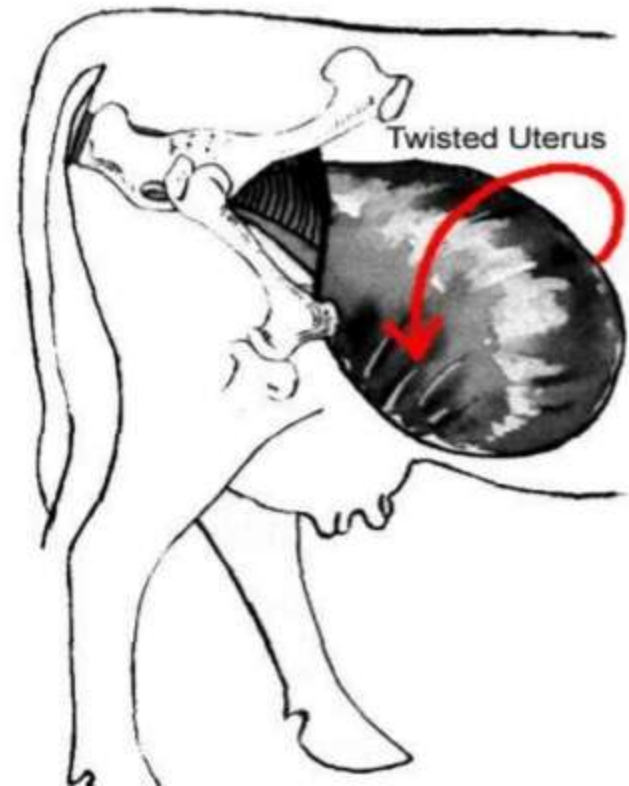
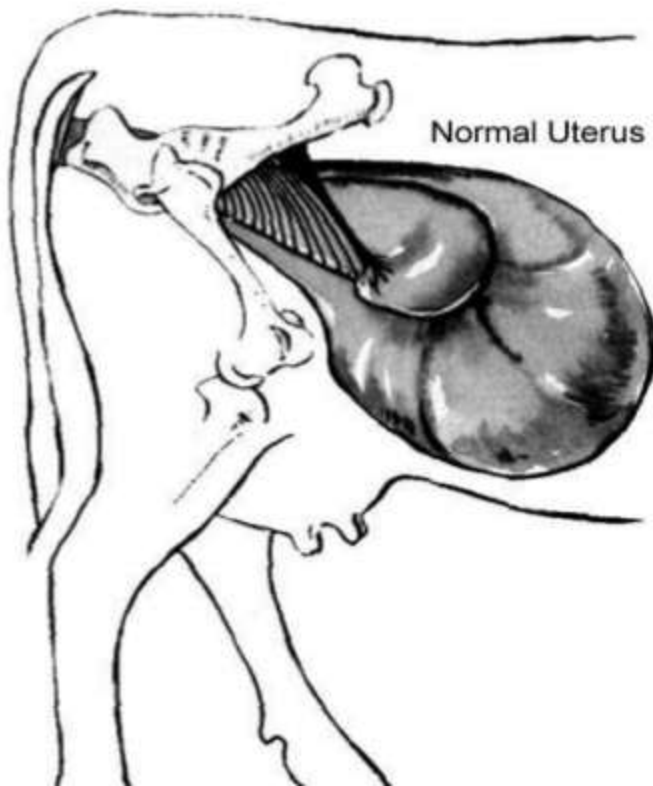
# UTERINE TORSION

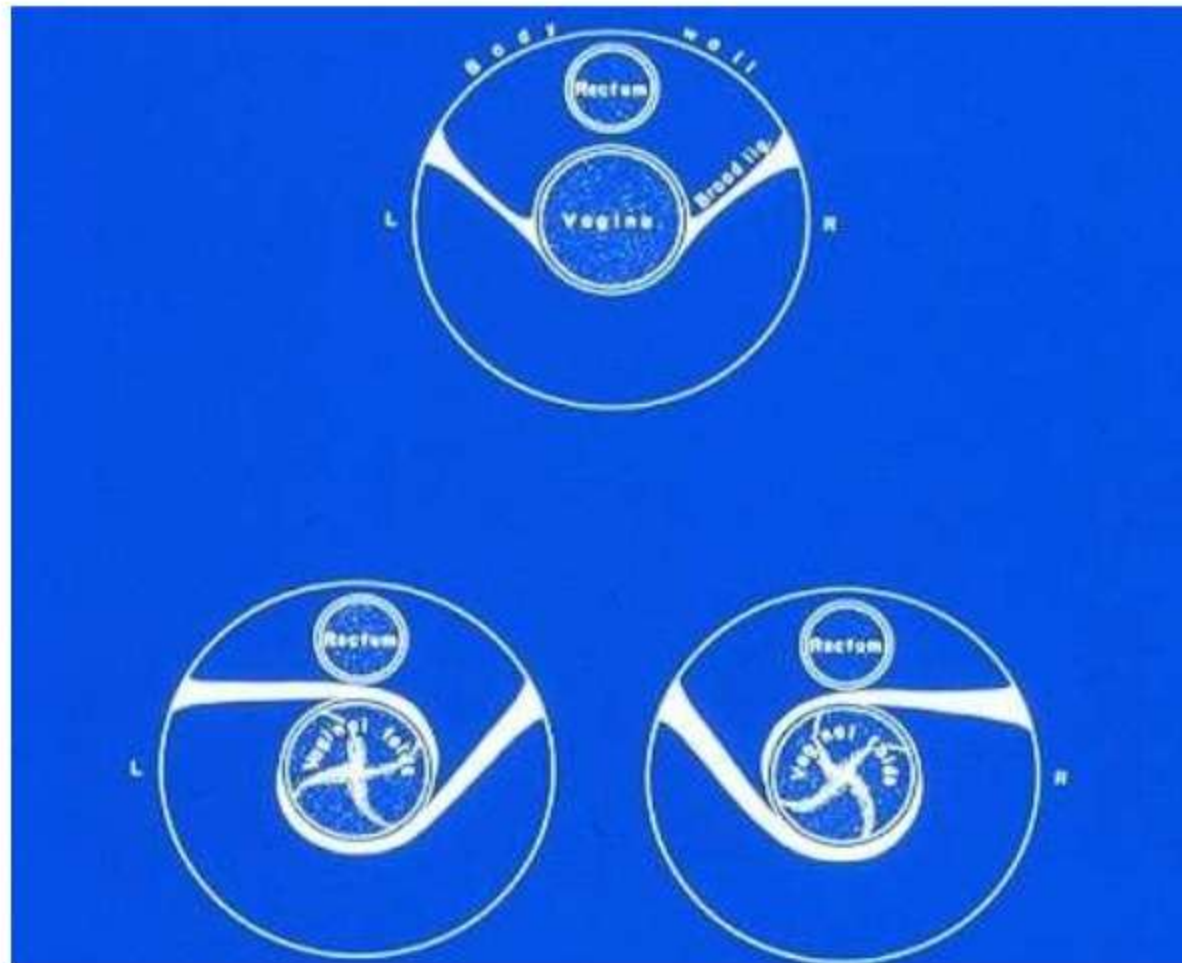
*DR. YASEEN M. RASHEED*



# UTERINE TORSION

- Torsion of uterus is the rotation of pregnant uterus on its longitudinal axis.





- The relative portion of the broad ligament is diagrammed for A) 180 degree right (clockwise) uterine torsion (lower left) B) 180 degree left (counter-clockwise) uterine torsion ( lower right).

# ETIOLOGY

- .INSTABILITY OF BOVINE UTERUS .**
- EXCESSIVE FETAL WEIGHT.**
- THE ANATOMICAL CAUSES –  
(SUBILEAL R.)**

attempting the cow to rise from sternal recumbency.



# Dx....

- The dorsal commissure of vulva may be pulled forward and to left or right.

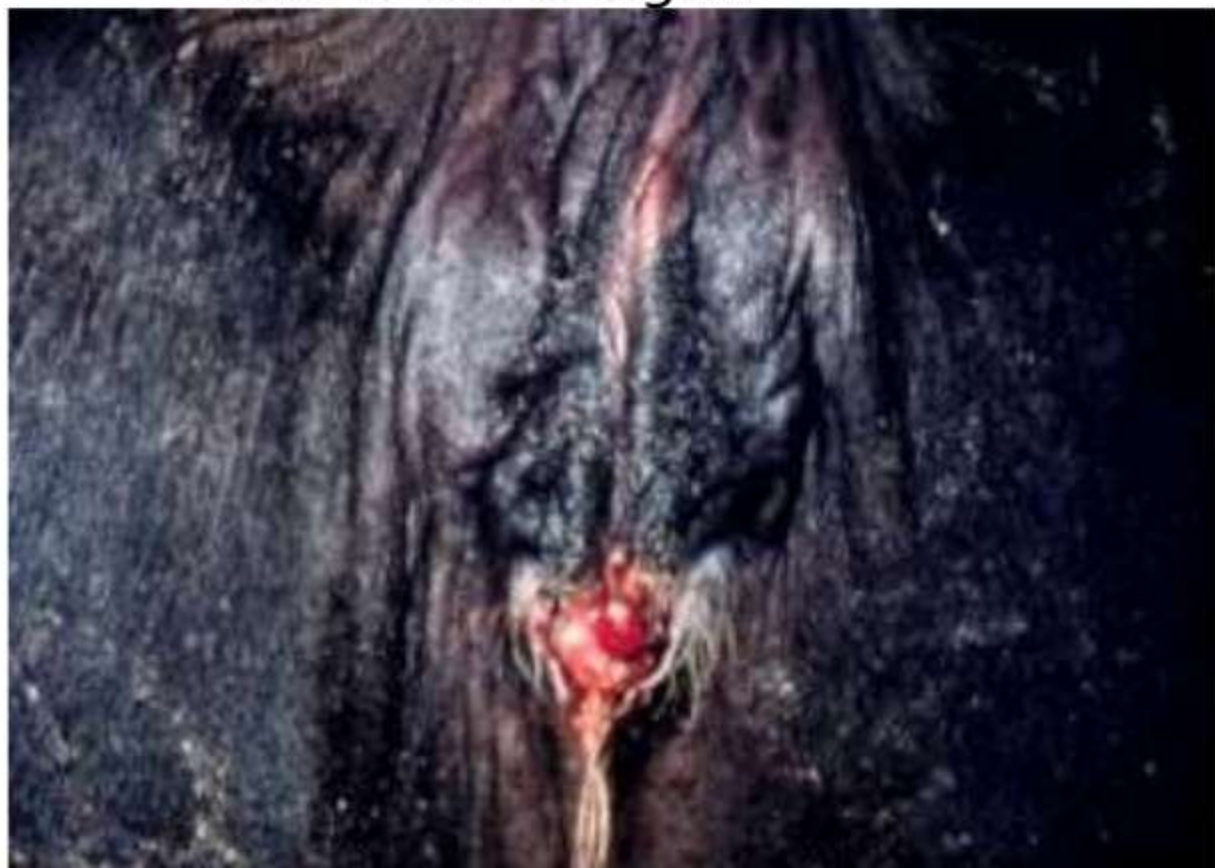

Fig: Twisting of the vulva due to right uterine torsion.

# Treatment

## 1-Non-surgical:

-Rotation of fetus per vagina, when the fetus is reached ,purchase is obtained on its shoulder or elbow region in order to rotate it in the *opposite direction* to the twist.

-Rolling of the Cow's body, the aim is to rotate quickly the cow's body in the *direction of the torsion* while the uterus remains relatively steady.

(Schaffer's method)  
rolling of dam using plank.

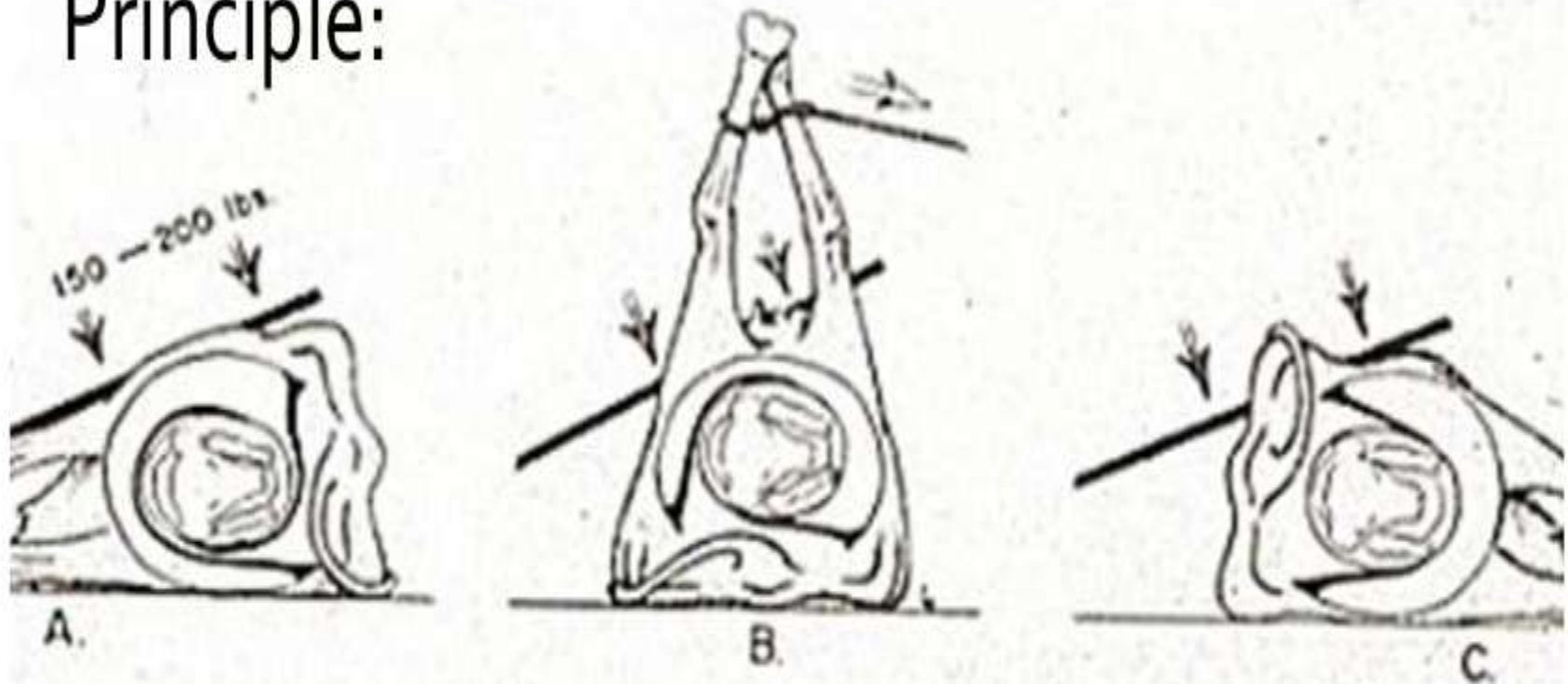


## 2-Surgical correction:

Laparotomy ,Caesarean Operation .

# Schaffer's method...

Principle:









**uteme torsion.mp4**